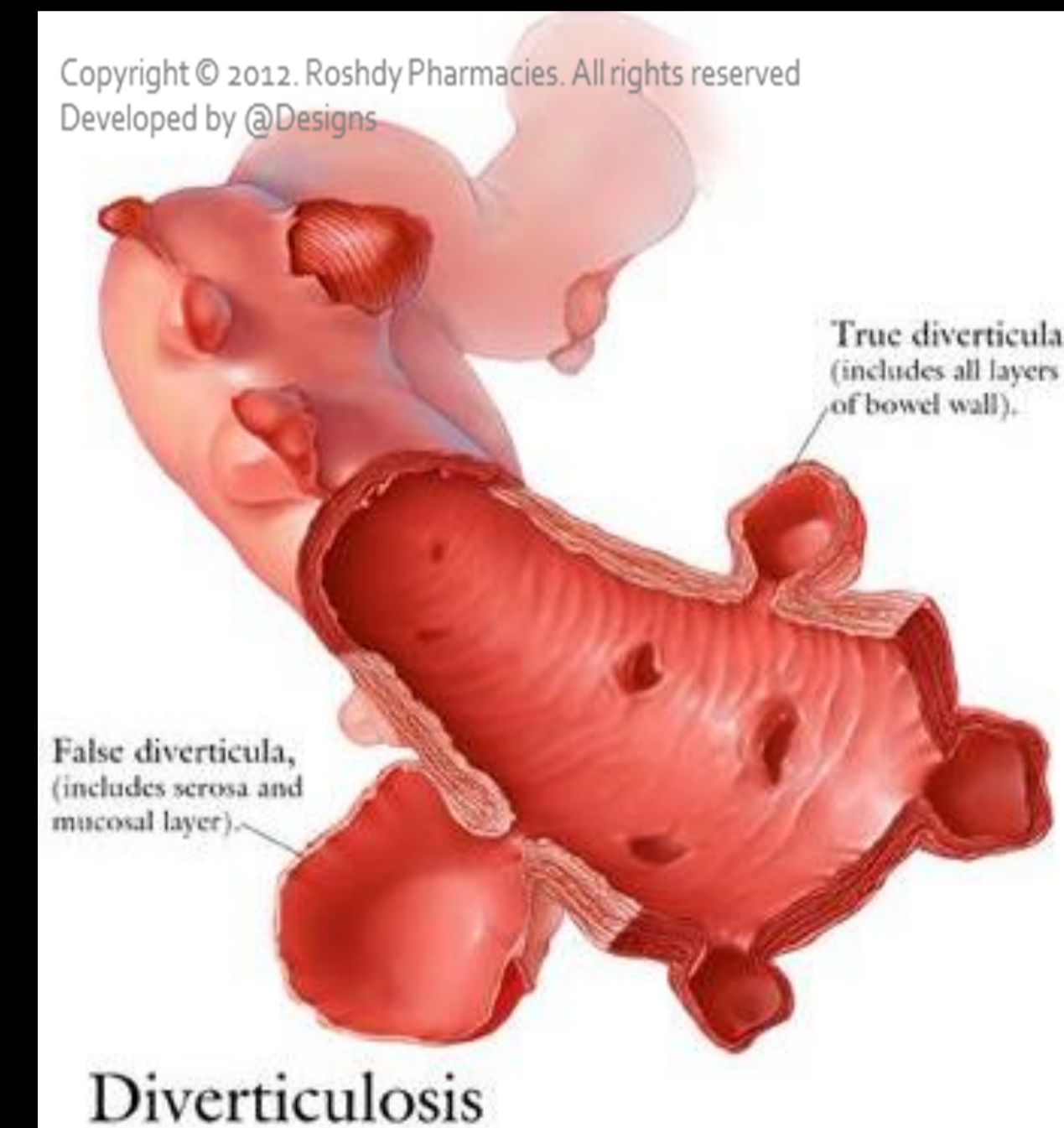


Jejunioleal Diverticulitis: Big Trouble in Small Bowel

MICHAEL CARUSO DO, HAO LO MD
EMERGENCY RADIOLOGY, UMASS MEMORIAL MEDICAL CENTER, WORCESTER, MA

LEARNING OBJECTIVES:

1. Be aware of the relatively rare diagnoses of jejunioleal diverticulosis (non-Meckelian) and diverticulitis.
2. Learn the epidemiology, pathophysiology, imaging findings and differential diagnosis of jejunioleal diverticulitis.



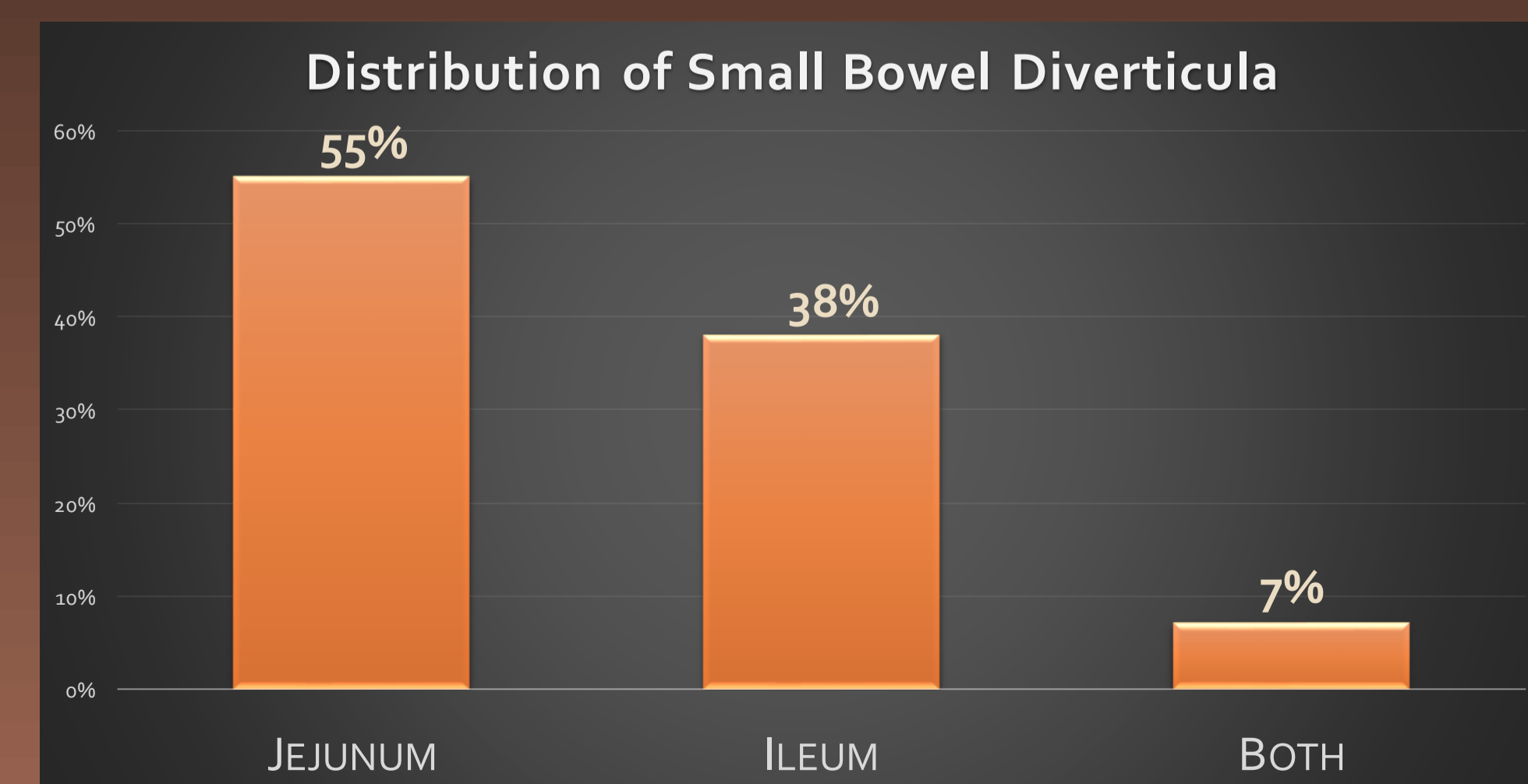
- ✓ **Diverticula** are sac-like protrusions of the bowel wall, which may be composed of mucosa and submucosa only (pseudodiverticula) or of all layers of the bowel wall (true diverticula)
- ✓ **Diverticulitis** is the result of obstruction of the neck of the diverticulum, with subsequent inflammation, perforation and infection.

EPIDEMIOLOGY (1)

- Rarely diagnosed prior to surgery or autopsy, until advent of CT
- Incidence of 1.3-4.6% for acquired diverticula of the jejunum and ileum
- 80-90% of affected individuals are more than 40 years old
- No predilection by race or gender
 - However, there is a preponderance of jejunioleal diverticula in males

ETIOLOGY

- Unknown. May develop from abnormalities in intestinal peristalsis, intestinal dyskinesia and very high intraluminal pressure, such as in the colon
 - Disorders of intestinal motility include progressive systemic sclerosis, visceral neuropathies, and myopathies
- Diverticula emerge only where mesenteric vessels penetrate into the muscular layer of the small intestine



- ✓ After excluding Meckel's diverticulum, less than 30% of reported diverticula occurred in the jejunum and ileum.
- ✓ Duodenal diverticula are approximately five times more common than jejunioleal diverticula.

Clinical History

- 70% of patients with diverticulosis are asymptomatic
- 15 - 25% have symptomatic disease resulting from diverticulitis (inflammation of a diverticula)
- 10 - 15% can have painless bleeding
- Acute symptoms are usually due to complications

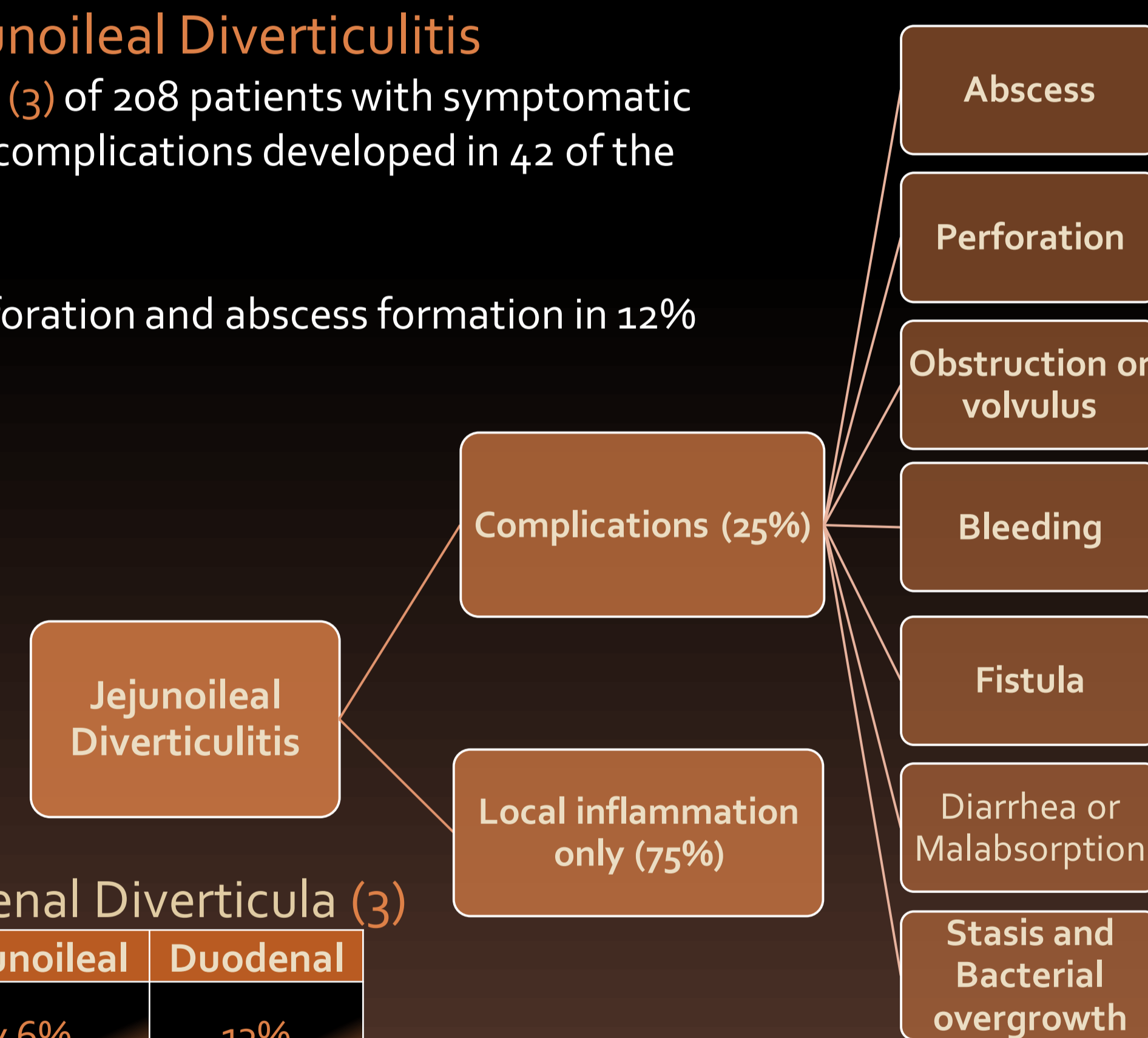
CT Findings (2)

- Usually presents as a focal area of bowel wall thickening most prominent on the mesenteric side of the bowel with adjacent inflammation and/or abscess formation
- When abscess is present, CT findings may include relatively smooth margins, areas of low attenuation within the mass, rim enhancement after IV contrast administration, gas within the mass, displacement of the surrounding structures, and edema of thickening of the surrounding fat or fascial planes

Complications of Jejunioleal Diverticulitis

In one retrospective review (3) of 208 patients with symptomatic small bowel diverticulosis, complications developed in 42 of the patients (20%) including:

- Bleeding in 14%
- Diverticulitis with perforation and abscess formation in 12%
- Malabsorption in 8%



Jejunioleal vs Duodenal Diverticula (3)

Diverticula	Jejunioleal	Duodenal
Presence of complications	46%	13%
Bleeding	12%	52%
Perforation/abscess	21%	1.20%

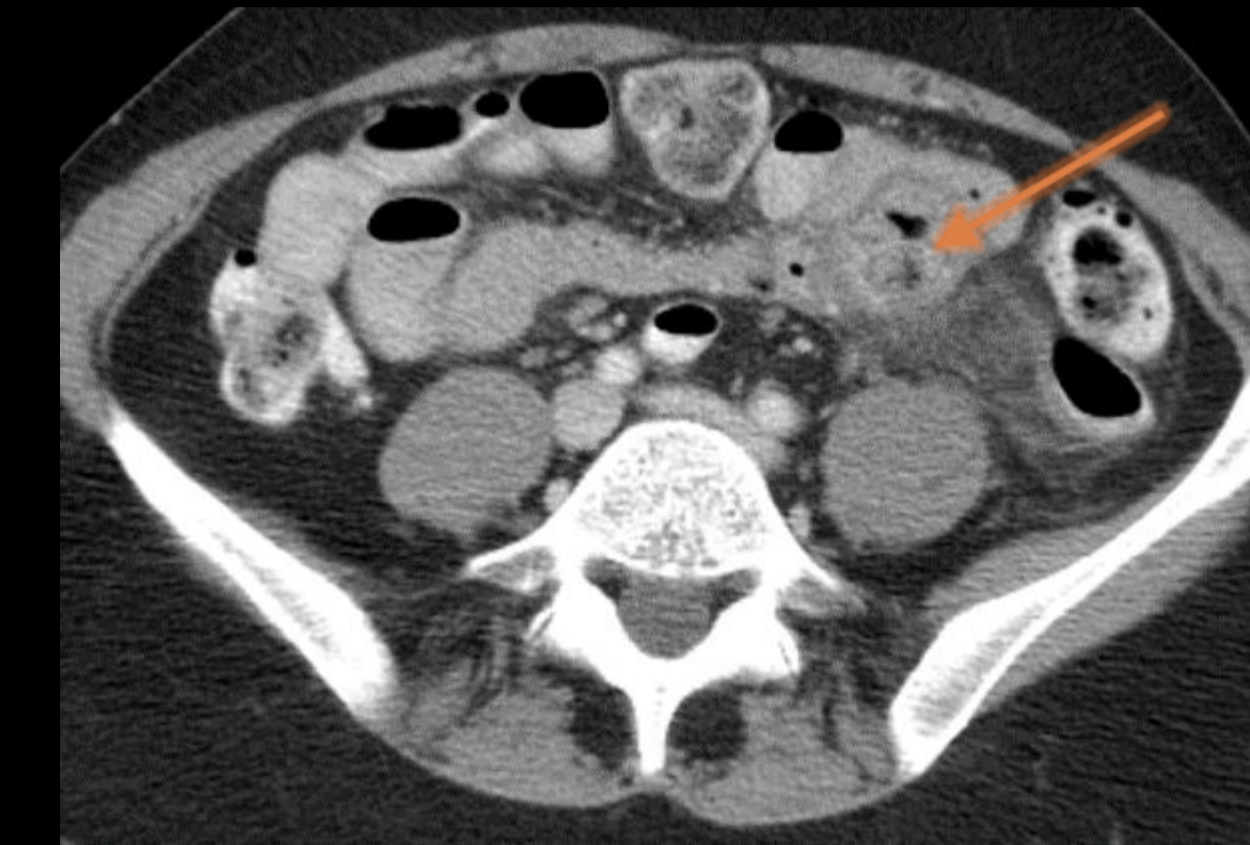
DIFFERENTIAL DIAGNOSIS

- **Diverticulitis:** outpouching from duodenum are very common; uncommon in remainder of small bowel
- **Lymphoma:** destroys wall of small bowel, necrotic tumor forms cavity in communication with bowel lumen
- **Metastases:** malignant melanoma is especially likely to cause aneurysmal dilation, similar to lymphoma
- **Bowel-Bowel Anastomosis:** common after prior small bowel resection, Roux limb, or to bypass stricture.
- **GIST:** duodenum is second most common site (after stomach), large, exophytic mass arising from duodenal wall
- **Small Bowel Obstruction:** chronically dilated small bowel may attain large diameter (> 6 cm).
- **Crohn Disease:** mesenteric fibrofatty proliferation, long segmental small bowel wall thickening, luminal narrowing, mesenteric hyperemia
- **Intestinal Scleroderma:** can cause sacculations that might simulate diverticula
- **Abdominal Foreign Bodies:** perforation of bowel by foreign body may cause extraluminal gas, fluid, inflammation.
- **Meckel Diverticulum:** congenital diverticulum within 2 feet of ileocecal valve, otherwise indistinguishable from other diverticula

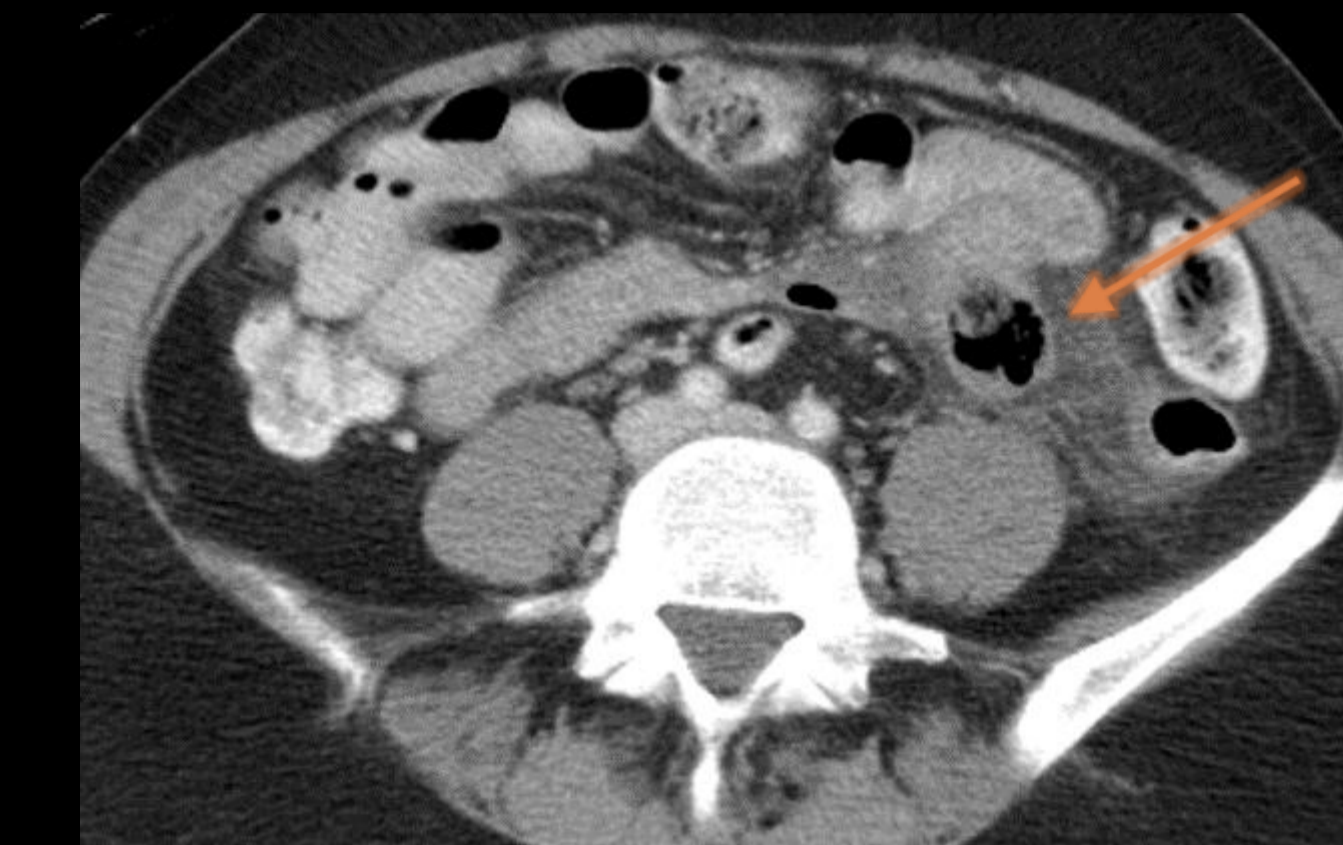CASE 1

HISTORY: 52 year old female with left upper quadrant pain.

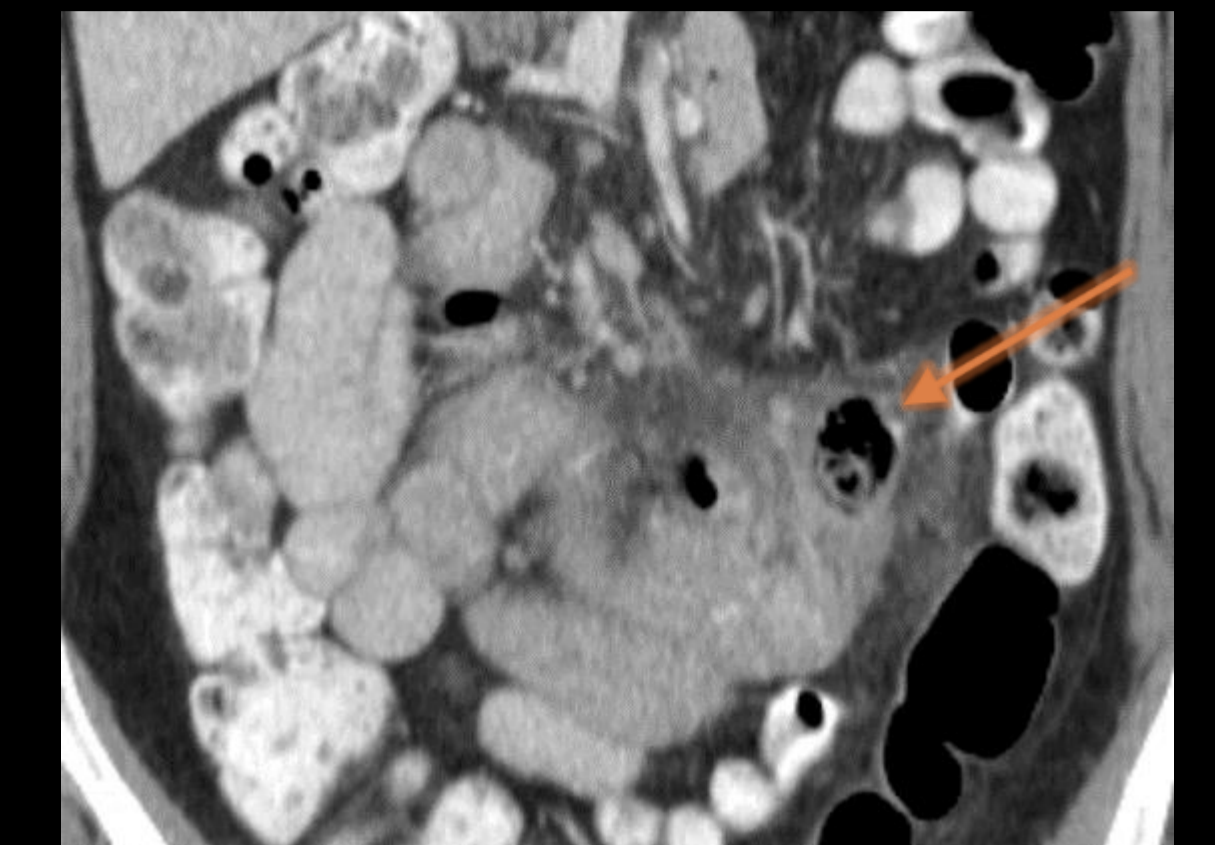
FINDINGS: 2.2 cm diverticulum extending from the distal ileum with adjacent induration of the mesenteric fat, consistent with an ileal diverticulitis.



AXIAL



AXIAL

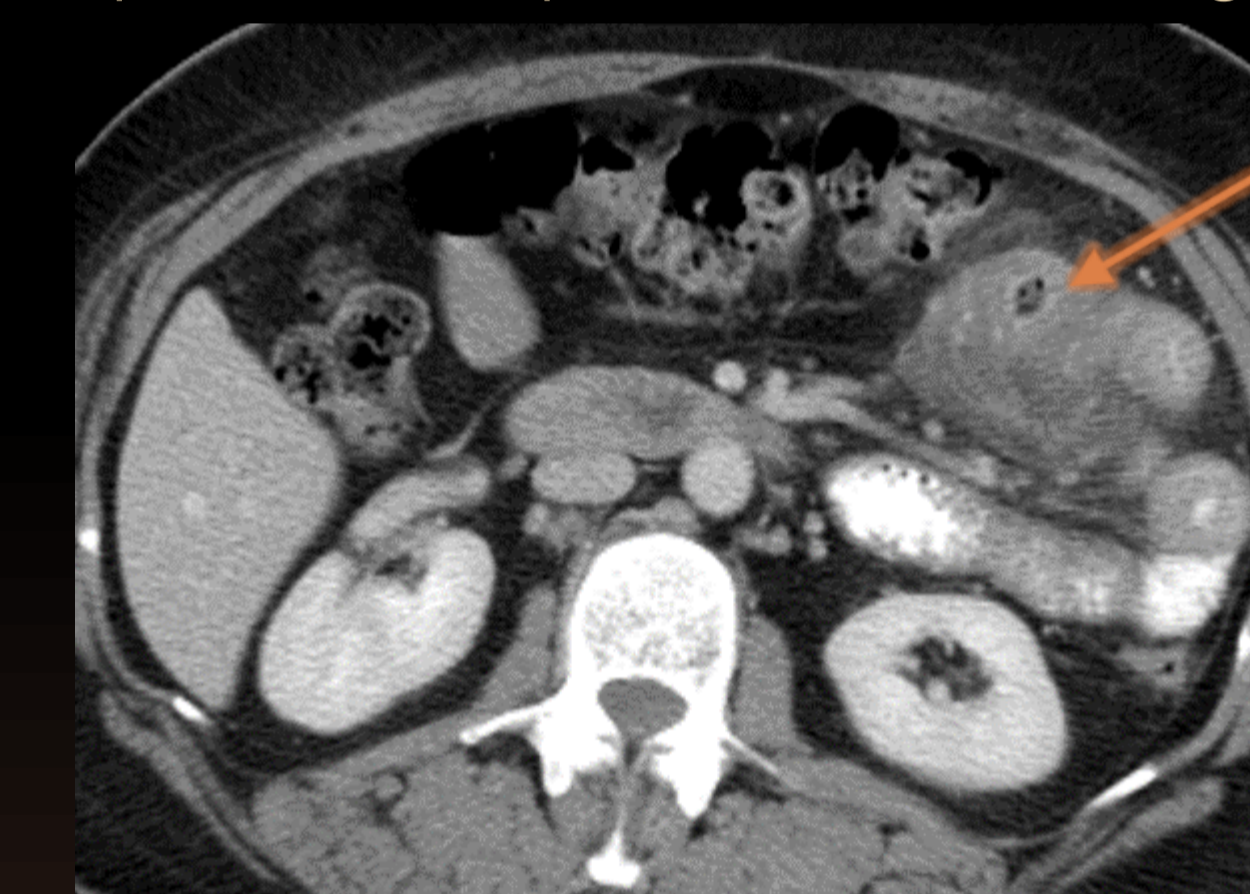


CORONAL

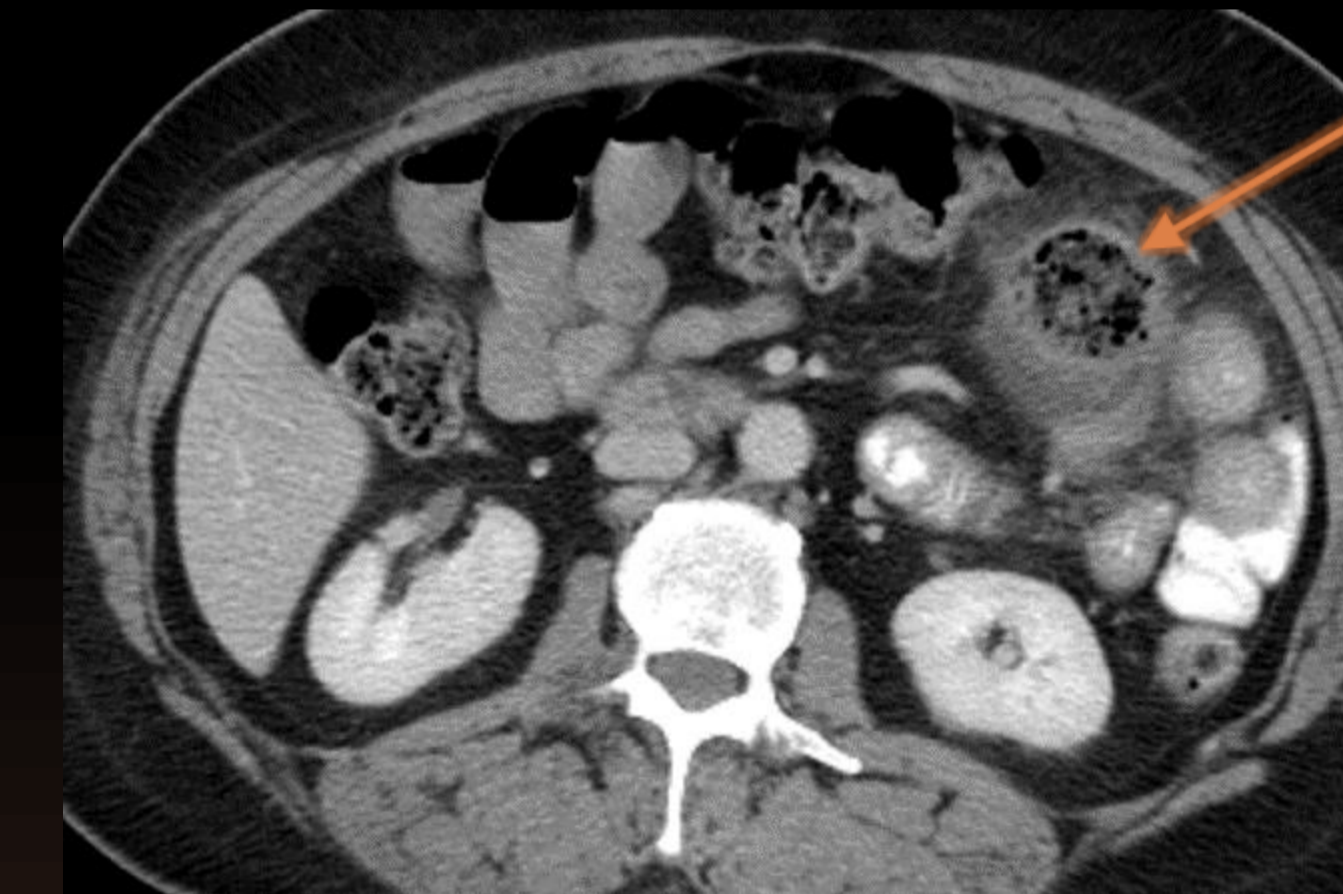CASE 2

HISTORY: 62 year old female with epigastric and left upper quadrant pain.

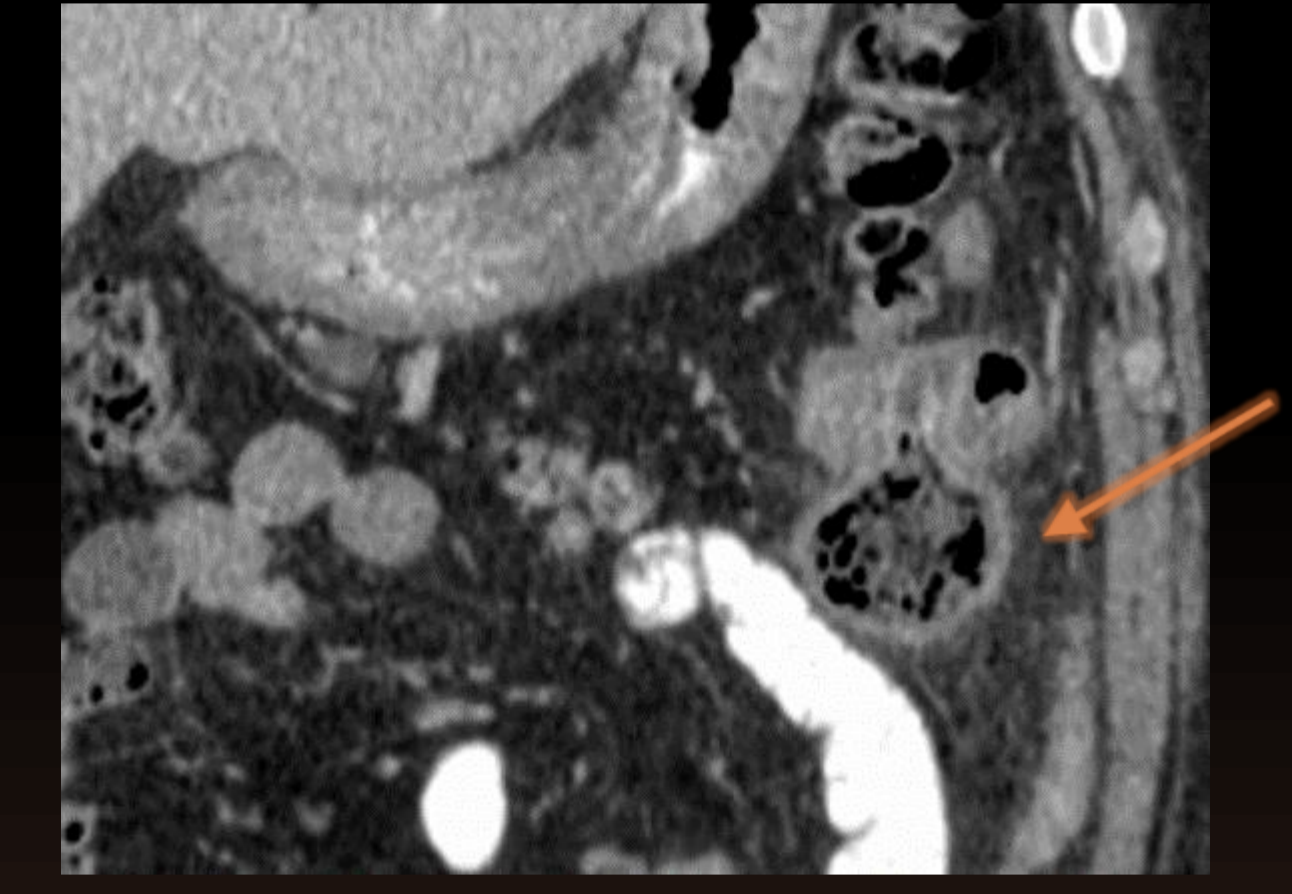
FINDINGS: 4.7 cm diameter out pouching seen arising from the proximal small bowel and associated with adjacent inflammatory stranding. The colonic loops were well separated from this finding.



AXIAL



AXIAL



CORONAL

Treatment

- Varies with severity
- Liquid diet, oral antibiotics for mild disease
- IV antibiotics, NPO for more severe disease
- CT-guided percutaneous drainage of abscess
- Resection and primary anastomosis is indicated if:
 - Perforated diverticular disease
 - Hemorrhage
 - Abscess formation after a failure of a short course of bowel rest and antibiotics

Specific Interventions for Diverticular Bleed

- Angiographic embolization can stop diverticular bleeding but causes bowel infarction in up to 20% of patients and is not recommended
- Bleeding stops spontaneously in about 75% of patients
 - Control can be achieved during angiography with intra-arterial vasopressin or during colonoscopy with coagulation or epinephrine injection

CONCLUSION

Diverticulosis in the jejunum and ileum is relatively rare compared to diverticula in the colon and duodenum. Jejunioleal diverticulitis is also correspondingly rare and can have subtle findings, but it is well demonstrated if the radiologist is aware of the diagnosis. Like colonic diverticulitis, jejunioleal diverticulitis can be medically-managed if the case is mild or uncomplicated, which can spare the patient unnecessary surgical interventions. The differential diagnosis of jejunioleal diverticulitis includes secondary inflammation from adjacent structure, perforated neoplasm, foreign body perforation, small-bowel ulceration from nonsteroidal anti-inflammatory drug use, and Crohn's disease. Major complications of jejunioleal diverticulosis and diverticulitis include gastrointestinal hemorrhage, gastrointestinal obstruction, acute perforation, intestinal obstruction, intestinal perforation, and localized abscess.

REFERENCES

1. Liu C-Y, et al. Analysis of clinical manifestations of symptomatic acquired jejunioleal diverticular disease. *World Journal of Gastroenterology* : WJG. 2005;11(35):5557-5560.
2. Fintelmann F, Levine MS, Rubesin SE. Jejunal diverticulosis: findings on CT in 28 patients. *AJR Am J Roentgenol*. 2008;190(5): 1286-90.
3. Akhrass R, et al. Small-bowel diverticulosis: perceptions and reality. *SOJ Am Coll Surg*. 1997;184(4):383.