

# Best Cases of the AIRP

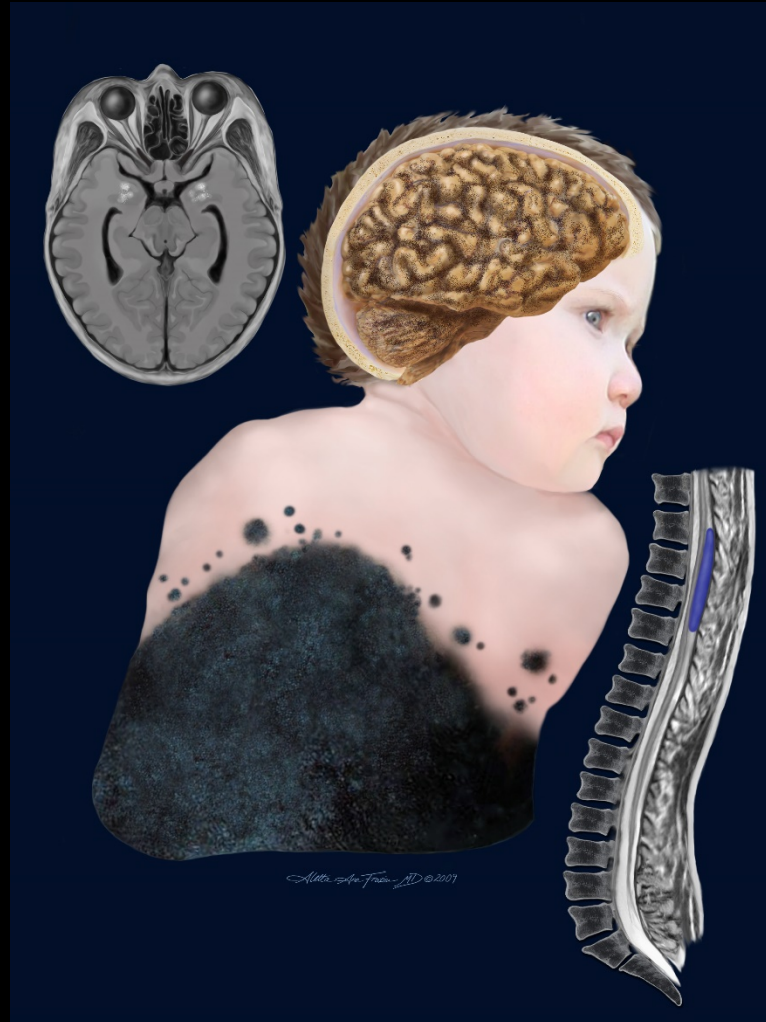February-March, 2020

**AIRP**<sup>TM</sup>

AMERICAN INSTITUTE FOR  
RADIOLOGIC PATHOLOGY

A PROGRAM OF THE  
AMERICAN COLLEGE OF RADIOLOGY

# Neuroradiology Best Case



**AIRP**<sup>TM</sup>

AMERICAN INSTITUTE FOR  
RADIOLOGIC PATHOLOGY

A PROGRAM OF THE  
AMERICAN COLLEGE OF RADIOLOGY

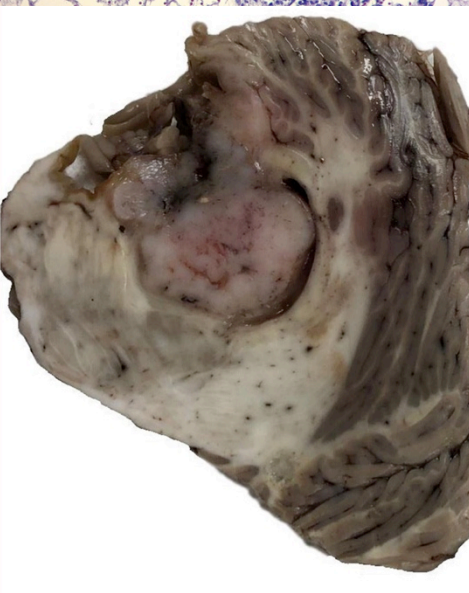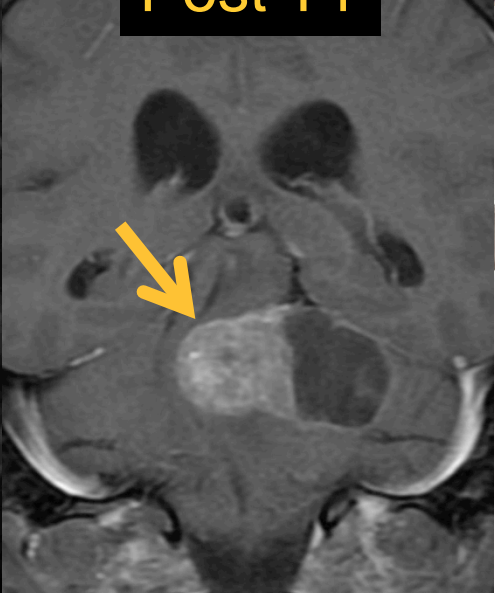
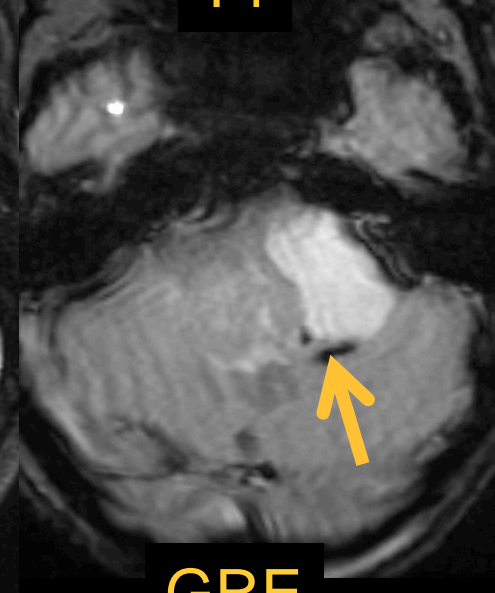
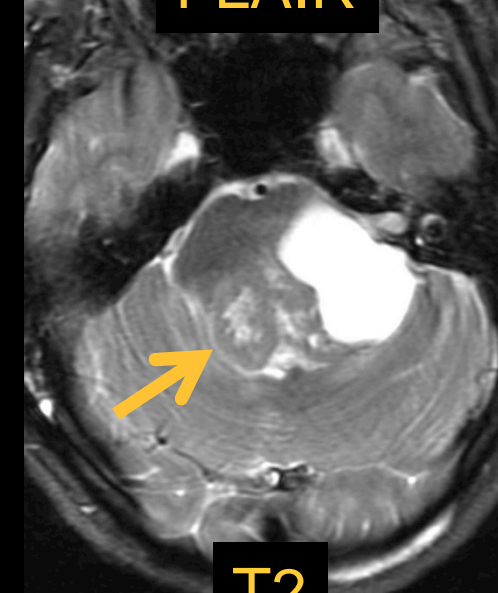
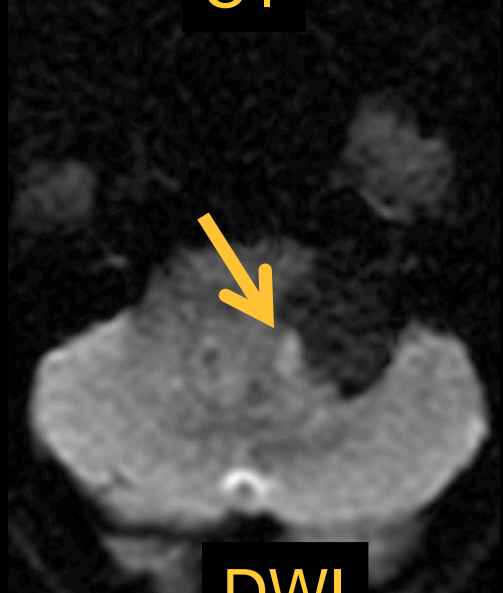
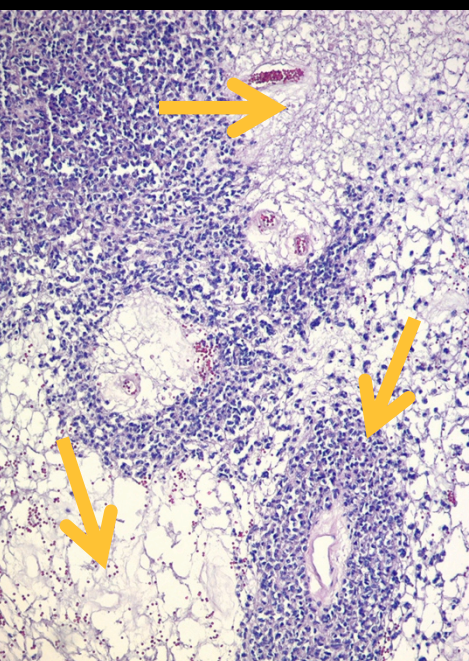
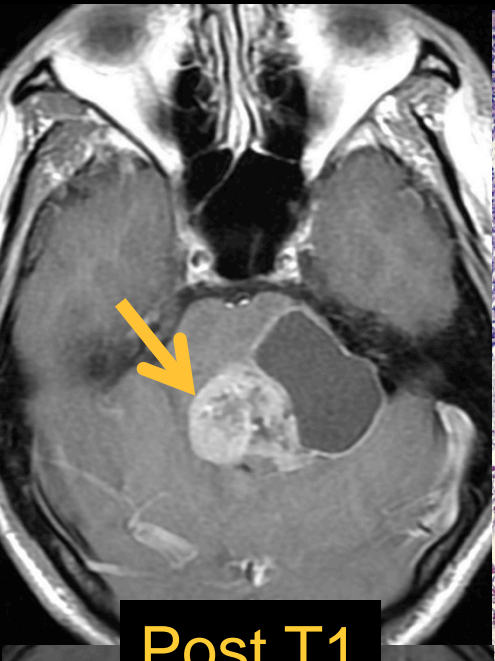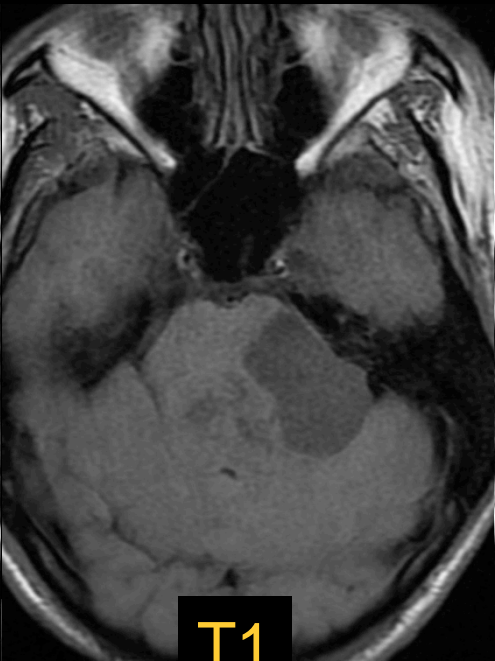
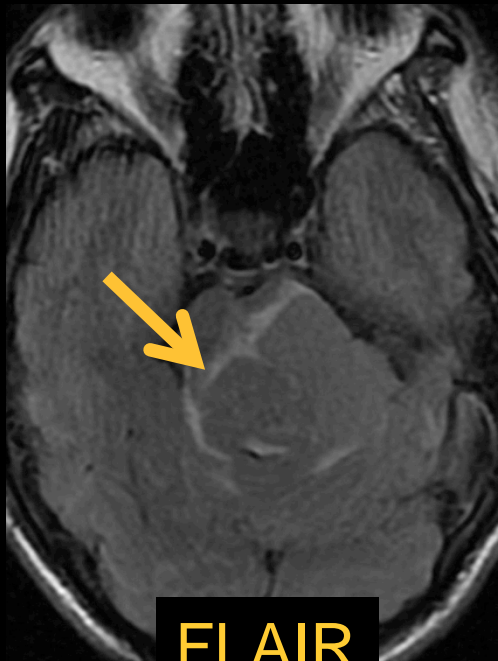
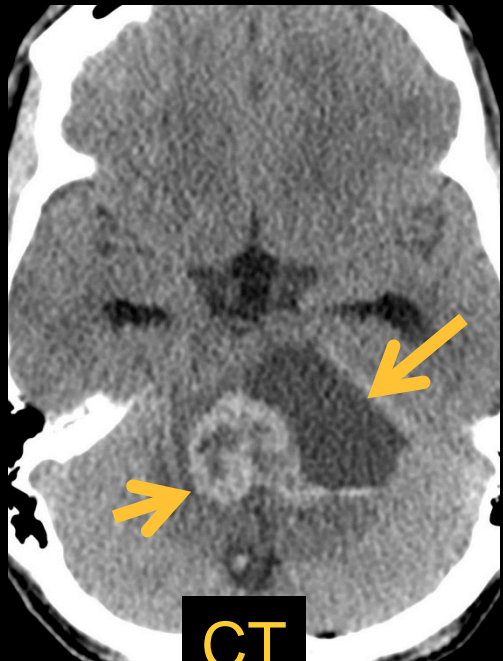# Clinical Information

35-year-old male with progressive gait disturbance, nausea, and vomiting.

**AIRP**<sup>TM</sup>

AMERICAN INSTITUTE FOR  
RADIOLOGIC PATHOLOGY

A PROGRAM OF THE  
AMERICAN COLLEGE OF RADIOLOGY





# Liponeurocytoma

Roberto Kutcher, M.D.

University of Massachusetts

Worcester, Massachusetts

**AIRP**<sup>TM</sup>

AMERICAN INSTITUTE FOR  
RADIOLOGIC PATHOLOGY

A PROGRAM OF THE  
AMERICAN COLLEGE OF RADIOLOGY